

# A rare localization of hydatidosis: A cervical hydatid cyst

Youssef Rochdi, MD - Abdelaziz Raji, MD - Youssef Elhattab, MD - Hassan Nouri, MD  
Fatima Bouchoua, MD - Youssef Narjisse, MD - Bahssine Ait Mbark, MD

Departments of ENT and Cervicofacial Surgery, Hospital El Antaki, Academic Hospital Mohamed VI (CHU), Marrakech, Morocco

## INTRODUCTION

Localized swellings of the cervical region can be ascribed to numerous causes. Parasitic causes, and particularly hydatid disease, are very rare, even in countries where echinococcus infestation is endemic. We report herein the case of primary cervical hydatid cyst in a 10-year old female patient and underline its rarity and the diagnostic issues caused by this location.

## CASE REPORT

Twenty-four hours after a needle aspiration of an anterior cervical tumor that showed a clear fluid, Ms A.R, a 10-year old female patient, was hospitalized with an incipient cervical cellulitis.

Her clinical history revealed a progressive painless increase in volume of this tumor over the past year without any contact with dogs, cattle, horses or any possible contamination sources. Post-puncture clinical examination showed a fluctuant, non tender, isolated anterior cervical mass of 5 cm in maximal diameter that was located half in the submandibular region and

(Fr ORL - 2007 ; 92 : 315 - 317)

(Présenté le 10- 12 octobre 2004 au congrès de la société française d'ORL et de chirurgie de la face et du cou, PARIS)

**Key words:** Hydatid cyst, Cervical, Surgery.

Submitted for publication: November 2005

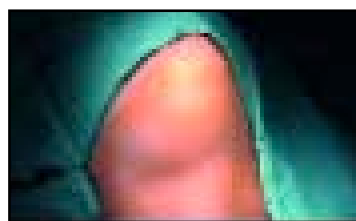
Accepted for publication: March 2007

**Corresponding author: Youssef Rochdi**

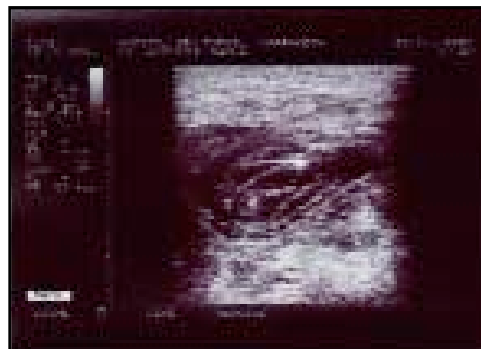Service d'ORL et Chirurgie cervico-faciale, hôpital El Antaki, CHU Mohamed VI, Marrakech, Maroc.

e-mail: rochdi\_86@hotmail.com

**Figure 1: Cervical swelling, half localized to the submandibular region and half to the right submaxillary region.**



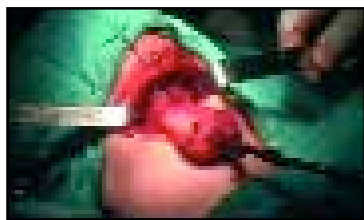**Figure 2: Cervical ultrasound showing a cystic image with floating membranes, highly suggestive of a hydatid cyst.**




half in the right submaxillary region (Figure 1). The floor of the mouth was edematous and inflamed without satellite lymph node. Hematological analysis showed an eosinophilia count of 384/mm<sup>3</sup> (normal values < 500/mm<sup>3</sup>, negative serological tests, with an indirect haemagglutination (IH) < 160. Cervical ultrasound showed a unilocular hypoechogenic structure of 5 cm in diameter filled with "floating membranes" consistent with a lobulated hydatid cyst (Figure 2); no other locations were found. Cellulitis regressed with parenteral amoxicillin-clavulanic acid treatment (1g/125mg every 12 h for two weeks) in association with anti-inflammatory treatment with diclofenac 25 mg every 8 h for 4 days.

## A cervical hydatid cyst

**Figure 3: Cystic mass touching the base of the tongue below the floor of the mouth and with adhesions to adjacent structures.**



**Figure 4: Opening of the tumor reveals the presence of a hydatid cyst.**



An exploratory cervicotomy was performed in the submandibular and right submaxillary regions and revealed a hydatid cyst (HC) in contact with the base of the tongue and adhering to adjacent muscles (Figures 3 and 4). A single-block cyst removal was performed including pericystic tissues. Hydrogen peroxide was used to sterilize the cystic cavity. Histological examination confirmed hydatid disease. There was no recurrence after 4 years of follow-up.

### DISCUSSION

Echinococcosis is a common parasitic disease in man and other mammals, mostly occurring in Mediterranean countries, South America, Australia, central Asia and East Africa [1- 2]. Localization within the soft tissues of head and neck is rare, whereas thyroid and parathyroid remain the most frequent sites of localization [1].

This parasitic disease is caused by the cestodes of the genus *Echinococcus*. Hydatid cyst is an infestation caused by the larval form of *Echinococcus granulosus*. The adult tapeworm lives in the intestine of the dog. From the dog intestine, the ova are passed into the stools and human infestation is done through direct contact with infected dogs or through ingestion of food contaminated by ova. Embryos penetrate through the intestinal wall and reach the liver by the portal vein. In the liver,

the embryos become adult cysts the majority of which are caught in the hepatic sinusoids; a few ova may pass through the liver, heart, and pulmonary capillaries and reach general circulation to lodge for instance in muscles.

Hydatid disease is rarely diagnosed on the evidence of a single cervical mass such as in the case that we observed in the absence of other localizations [14]. Differential diagnosis would be a cold abscess, a congenital cyst or a benign tumor. However, typically, echinococcosis consists of a single, unilocular cyst; however, 20% to 30% of cases may have several cysts in 1 organ or 1 cyst in multiple organs. The clinical outcome could be complicated by clinical signs of laryngotracheal compression [6] and regional infection after needle aspiration or cyst rupture. Aspiration of a clear fluid could confirm the diagnosis, but is contraindicated because of the risk of parasitic dissemination and anaphylactic shock.

Echographic characteristics of cervical HC are similar to visceral ones, with a multicystic appearance being typical (4). In our patient, the suspicion of HC with floating membranes was reinforced by aspiration of clear fluid after needle puncture. Computerized tomographic scanner is a helpful diagnostic when it shows parietal calcifications and an absence of density enhancement after contrast injection into the heterogenic structure of HC.

Hypereosinophilia is frequently absent [6,12]. In 80 -90% of cases positive serological tests make a diagnosis, however, negative results does not rule out the diagnosis. There are at least two serological diagnostic techniques [7]: quantitative (indirect immunofluorescence, IH, ELISA) and qualitative (Immunoelectrophoresis). Post-operative increases in serological levels are consistent with a recurrence. [3].

Treatment is based on the total removal of the cyst in a single block, peri-cystectomy or a resection of the prominent cyst dome in the case of adhesions to neurovascular structures or to the aero-digestive tract, with subsequent sterilization of the operation field with hypertonic saline and hydrogen peroxide [1, 6,11]. Imidazole derivatives are indicated for inoperable lesions [8], but there is no consensus about the duration of such treatment. Postoperative albendazole or imidazole derivatives therapy are suggested especially when there is preoperative contamination risk [13].

### CONCLUSION

Cervical location of hydatid disease is rare but not exceptional. It must be considered in every case of an isolated mass, especially in a context where echinococcosis is endemic even in absence of other disease sites. Ultrasound facilitates diagnostic and therapeutic procedures in view of a complete surgical removal.

### REFERENCES

1. Abi F, Fares F, Khaiz D, Bouzidi A. Les localisations inhabituelles du kyste hydatique, A propos de 44 cas. *J Chir Paris*. 1989; 126: 307-312.
2. Bouckaert MMR, Raubenheimer EJ, Jacobs FJ. Maxillo-facial hydatid cysts. *Oral Surg Oral Med Oral Pathol Oral Radiol Endod*. 2000; 89: 338-342.
3. Gangopadhyay K, Abuzeid M, Kfoury H. Hydatid cyst of the pterygopalatine-infratemporal fossa. *J Laryngol Otol*. 1996; 110; 10: 978-980
4. Kehila M, Allegue M, Abdessalem M et al. Le kyste hydatique du muscle psoas, A propos d'un cas. *J Radiol*, 1987; 68: 256-268.
5. Petavy AF, Deblock S, Walbaum S. Épidémiologie et prévention des echinococcose en France. *Rev Prat Paris*, 1990; 40: 191-197
7. Zerhouni. H, Amrani A, Kaddouri N, Abdelhak M, Benhmamouch N, Barahioui M. Dyspnée laryngée révélatrice d'une localisation cervicale d'hydatidose : à propos d'un cas. *Arch Pédiatr*. 2001; 8: 1341-1343.
8. Biava MF, Kures L. Diagnostic biologique des échinococcoses. *Rev prat*. Paris, 1990, 40; 3: 201-204.
9. Onder G, Kayhan O, Yalc\_n K, Olcay E, Osman A. Submandibular and intracranial Hydatid Cyst in an Adolescent. *Laryngoscope*. 2002; 112: 1857-1860.
10. Katilmi\_ H, Oztürkcan S, Ozdemir I, Adadan Güvenç I, Ozturan S. Primary hydatid cyst of the neck *Am J Otolaryngol*. 2007 May-Jun;28(3):205-7.
11. Ammar J, Grairi H, Hammami S, Hantous S, Hamzaoui A. Hydatid cyst: another unusual localization. *Rev Pneumol Clin*. 2005 Oct;61 (5 Pt 1):312-4
12. Adaletli I, Yigiter R, Selcuk D, Sirikci A, Senyuz OF. Primary hydatid cyst of the head and neck diagnosed with ultrasound and computed tomography: a report of two cases. *South Med J*. 2005 Aug;98(8):830-2.
13. Bozbuga M, Celikoglu E, Boran BO. Hydatid cyst of the craniocervical junction: case report. *Neurosurgery*. 2005 Jul;57(1):E193; discussion E193.
14. Akal M, Kara M. Primary hydatid cyst of the posterior cervical triangle. *J Laryngol Otol*. 2002 Feb;116(2):153-5.