

Giant sphenoid mucocele: A case report

Yasser Arkha¹, MD - Salma Benazzou², MD - Abdessamad El Ouahabi¹, MD - Leila Essakalli²,
Mohammed Kzadri², MD - Abdeslam El Khamlichi¹, MD

¹Neurosurgery Department, Hospital of Specialities, Academic Hospital Avicenne (CHU), Rabat, Morocco

²ENT Department and Department of Maxillofacial Surgery, Hospital of Specialities, Academic Hospital Avicenne (CHU), Rabat, Morocco

INTRODUCTION

A mucocele is a benign, expansive, locally destructive cystic formation, which develops from a nasosinusal cavity [1]. The most frequent sites are frontal and fronto-ethmoidal; sphenoid forms are more rare (1-2% of sinus mucoceles) [2]. Clinical symptoms are non-specific with a delayed appearance reported in the development of sphenoid mucoceles. CT-scan and magnetic resonance imaging (MRI) permit presumptive and early diagnosis to be made. The treatment of choice is sphenoidectomy by the endonasal approach with mucocele drainage.

CASE REPORT

Mrs. A.F, aged 47 years, with no previous medical history of note, presented after 6 years of diffuse headaches associated with a right ocular protrusion that was increasing progressively in volume. The evolution was marked by a progressive decrease of visual acuity, resulting in blindness on the right side for the last 3 years, for which the patient did not seek medical attention.

Considering the aggravation of this exophthalmos, the appearance of a swelling in the right temporal region with a homolateral nasal obstruction was regarded as an emergency. The admission examination revealed that the patient was conscious and well oriented in time

Key words: Mucocele, Sinus, Sphenoid.
(*Fr ORL - 2007 ; 92 : 312 - 314*)

Submitted for publication: July 2005

Accepted for publication: January 2007

Corresponding author: Yasser Arkha
BP. 6626 Rabat instituts - Madinat Al Irfane
Rabat MAROC
e-mail: yassernch@hotmail.com

and space. She presented with a right temporal 6 cm-diameter tumor with a soft consistency, non-pulsatile and with no visible signs of inflammation. Ophthalmologic examination showed a non-reducible, right axial exophthalmos that was associated with conjunctival redness and right-sided blindness. Neurological examination was unremarkable except for involvement of the II cranial nerve on the right.

Nasal endoscopy showed a right nasal fossa totally blocked by an expansive process from right middle meatus that was suppressing the right inferior and middle conchae and was in contact with the floor of the nasal fossa. The left nasal fossa was clear. The ENT examination was otherwise normal.

Radiography using Blondeau's view showed a watery-toned opacity projecting to the orbital region with destruction of the sphenoid cleft and the lesser wing of the sphenoid bone.

Cranio-facial CT-scan demonstrated a liquid-dense disease process of the greater wing of the sphenoid extending to the corpus sphenoidale, the ethmoid, the orbit with lysis of orbital roof and wall, the right maxillary sinus, the right nasal and pterygo-maxillary fossae with lysis of temporal bone and extension into soft tissues. This process had an intracranial extension at the level of right frontotemporal region that was separated from cerebral parenchyma by a hyperdense region (Figures 1a and 1b).

Craniofacial MRI suggested that the sphenotemporal process was of mucocelic nature and for this reason the patient was treated using a right endoscopic endonasal approach.

Marsupialisation of mucocelic cavity permitted its drainage and clearance of the right nasal fossa (Figures 2a et 2b).

Post-operative follow-up was uncomplicated and was marked by regression of the exophthalmos without

Figure 1a: Cerebral CT-scan, axial cut. *Voluminous speno-temporal process, isodense, expanding to the ethmoid and the orbit.*

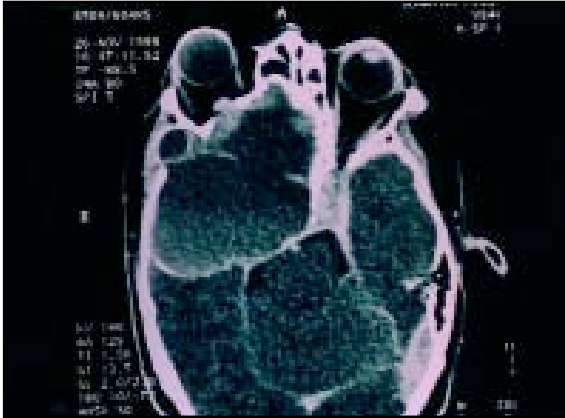

Figure 1b: Cerebral CT-scan, coronal cut. *Upward extension of the lesion to the right pterygomaxillary fossa with lysis of temporal bone and extension into soft tissues.*

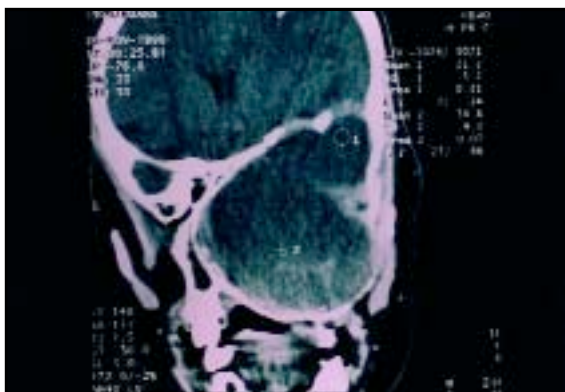


Figure 2a: Cerebral MRI, sagittal cut, time constant T1. *Isointense sphenotemporal process with exocranial extension.*

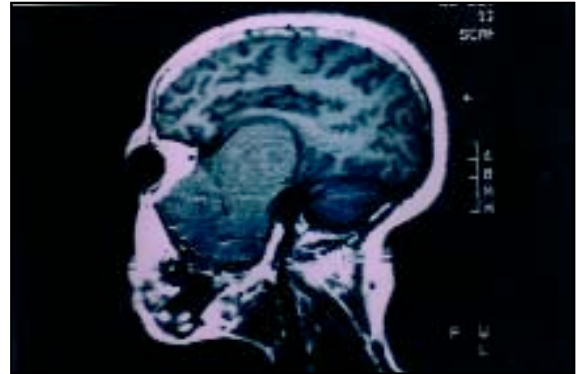


Figure 2b: Cranio-facial MRI, coronal cut, time constant T2. *Hyperintense process, expanding to the right temporal and pterygomaxillary fossae.*

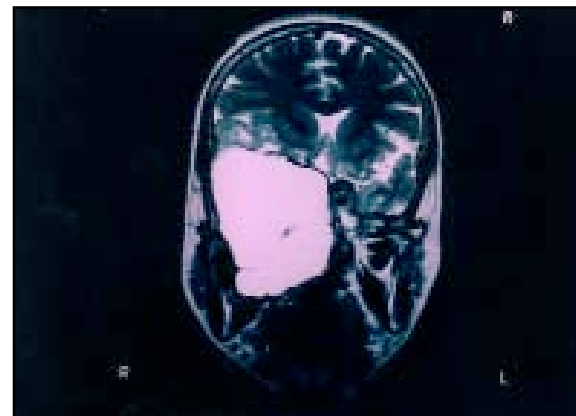
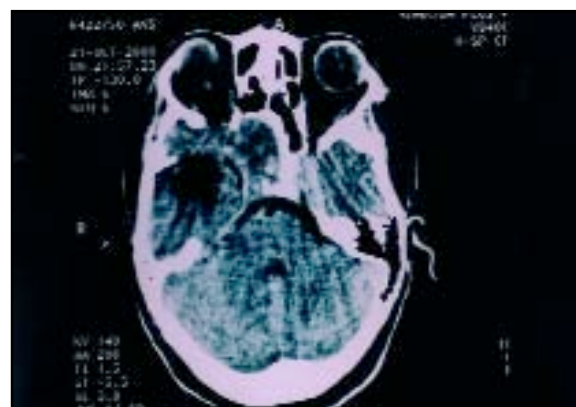


Figure 3: Cerebral CT-scan, axial cut, control. *Right frontotemporal image, hypodense with reconstruction of the osseous wall.*



recovery of vision. No clinical recurrence was noted during a 4-year interval. A control craniofacial CT-scan showed the resulting right frontotemporal image with reconstruction of the osseous wall (Figure 3).

DISCUSSION

Sphenoid mucocele is rare entity, most often reported in the literature as clinical cases. One hundred and forty cases have been noted since its description by Berg in 1889 [2-3]. A weak male predominance (53%) has been found among those aged 30-60 year [3]. Our observation adds a new case of sphenoid mucocele that was characterized by its size and extension.

Clinical symptomatology is very broad and non-specific. The delay in diagnosis varies from 3 days to 38 years with a mean delay of 4 years. The most characteristic clinical sign is the presence of diffuse, periorbital headache (90%). Ophthalmic involvement is frequent with exophthalmos, decrease in visual acuity, amaurosis, oculomotor paralysis, visual field alterations and/or IIIrd cranial nerve involvement being found. ENT manifestations such as anosmia, nasal obstruction and nasal discharge have been reported also, as have endocrine problems and panhypopituitarism [1-3].

Advances in imaging techniques (CT-scan, MRI) facilitate the diagnosis of sphenoid mucoceles, precise assessment of extension and allow morphologic nasosinus assessment. The mucocele is a homogenous formation with clear contours. Spontaneously hypodense and isodense on CT-scan, it can be hyperdense in older types. On MRI it appears more often hyperintense on T2 with peripheral and intra-lesion uptake of contrast. In the case of a voluminous sphenoid process with extrasinus extension (as in our case report), imaging with multiple transverse, frontal and sagittal cuts permits confirmation of the sphenoid sinus origin [1, 3-4]. Thus, when the diagnosis of a sphenoid mucocele is suspected after imaging an endoscopic approach is recommended. Endonasal endoscopic guidance gives access to the sphenoid-ethmoid recess, which is punctured and a wide marsupialisation of the mucocelic pouch is performed, which allows its evacuation. The endoscopic approach is particularly recommended in giant mucoceles with intra and extracranial extension because it is a non invasive surgery with low risk of perforation of the dura mater, which is hardened by inflammation and resistant to pressure [5].

CONCLUSION

Sphenoid mucoceles are rare. They display different clinical and radiological features. Marsupialisation using the endoscopic endonasal approach is the treatment of choice.

REFERENCES

1. Klossek JM, Dufour X, Ferrie JC, Fontanel JP. Pneumosinus dilatans et mucocèles des cavités nasosinusiennes. *Encycl Méd Chir (Elsevier, Paris), Oto-rhino-laryngologie*, 20-465-A-10. 2003, 8p.
2. Kosling S, Hintner M, Brandt S, Schulz TH, Bloching M. Mucoceles of the sphenoid sinus. *Eur J Radiol* 2004; 51:1-5.
3. Hejazi N, Witzmann A, Hassler W. Ocular manifestations of sphenoid mucoceles : clinical features and neurosurgical management of three cases and review of the literature. *Surg Neurol* 2001; 56: 338-343.
4. Ferrie JC, Klossek JM. Les mucocèles sphénoïdales. *J Neuroradiol* 2003; 30: 219-223.
5. Har-El G. Endoscopic management of 108 sinus mucocèles. *Laryngoscope* 2001; 111: 2131-2134.