

Giant pleomorphic adenoma of the nasal fossae

Mourtada Faissal¹, MD - Essakali Leila¹, MD - El Kohen Asma¹, MD - Jamal Hicham¹, MD - Nabih Nabila², MD
Jazouli Nezha¹, MD - Kzadri Mohamed¹, MD

¹ OENT department –Hospital of Specialities- Rabat Academic Hospital (CHU) - Morocco

² Department of Pathological Anatomy – Hospital of Specialities - Rabat Academic Hospital (CHU) - Morocco

INTRODUCTION

The giant pleomorphic adenoma is a benign heterogeneous tumor of salivary glands composed of several tissue components that are epithelial and myoepithelial in nature. It occurs frequently in the large salivary glands, but may also present exceptionally at other sites, particularly the nasal fossae. We report a case of a giant pleomorphic adenoma of the nasal fossa treated by a paralateronasal rhinotomy.

CASE REPORT

A 73-year old Caucasian patient that was being treated for systemic arterial hypertension and diabetes suffered progressive left nasal obstruction for 2 years which was associated with recurrent bilateral anterior epistaxis of small volume, without evidence of rhinorrhea. The development of the obstruction was characterised by the appearance of a swelling at the root of the nose that increased progressively in volume and generated a telecanthus. (Figure1)

Rhinoscopy revealed a pink-white polypoid formation filling both nasal fossae entirely without involvement of the nostrils.

Key words: Pleomorphic adenoma, Nasal fossae.

(*Fr ORL - 2007 ; 92 : 309 - 311*)

Submitted for publication: February 2006

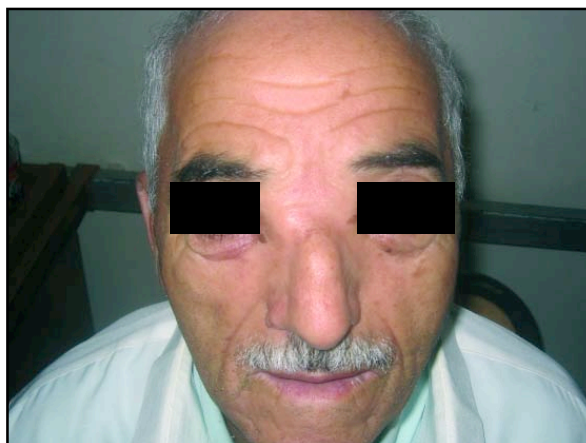Accepted for publication: January 2007

Corresponding author: Mourtada Faissal

BP n°6549, Madinat el Irfane, Rabat, Morocco

e-mail: mourtadafaissal@yahoo.fr

Figure 1: Swelling of the base of the nose with telecanthus



Nasal endoscopy confirmed these data and permitted several biopsies to be taken for histological analysis. The histology confirmed the diagnosis of a pleomorphic adenoma.

A nasosinusal CT-scan demonstrated a lesion that involved the left side of the nasal fossa, anterior ethmoid and frontal sinuses expanding to the right nasal fossa and frontal sinus with lysis of the septal cartilage. We also noted a blown appearance of the two laminae papyraceae and the ethmoid roof with endocranial extension (Figures 2-4).

Surgical removal via the paralateronasal approach was proposed. This allowed us to identify lysis of the anterior ethmoid with a fluid-filled mass, which when punctured revealed a brownish liquid suggestive of a bilateral ethmoido-frontal pyocele.

Careful dissection of the mucocele wall revealed an underlying tumoral process at the left nasal fossa that

Giant pleomorphic adenoma of the nasal cavity

Figures 2, 3: Axial and coronal CT scan (parenchymatous window) showed a lesion involving the left nasal fossa and the anterior ethmoid expanding to the right fossa through nasal septum with right endocranial and intraorbital extension

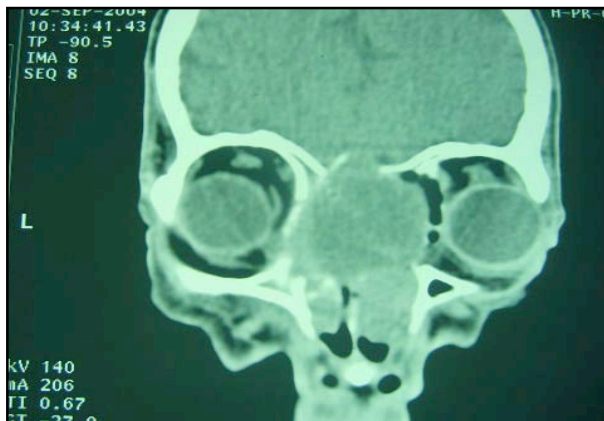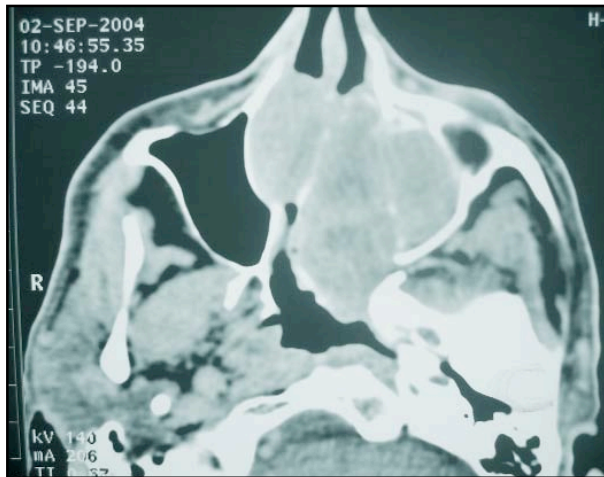
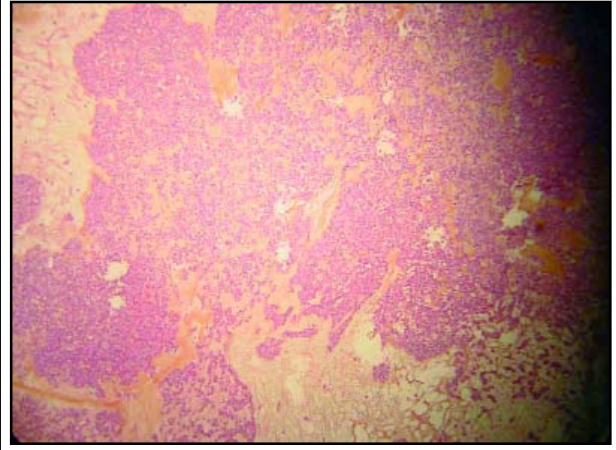


Figure 4: Axial naso-sinus CT scan that shows lysis of posterior wall of frontal sinus with endocranial extension

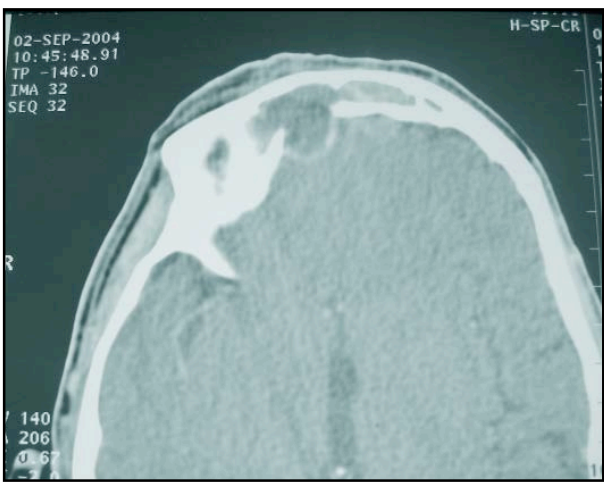

Figure 5: Hematoxylin-Eosin-Safran x 100, proliferation of dual epithelial component within a chondro-myxoid stroma



extended to the inner right nasal fossa. Histological examination of the mass confirmed the results of the biopsy. Step by step removal of the entire tumor was performed. The definitive pathological examination of the resected area confirmed the diagnosis of a pleomorphic adenoma (Figure 5).

Endoscopic revision of the nasal fossae 15 days later showed some scars and no residual tumor. At follow-up one year later there was no sign of recurrence.

DISCUSSION

Pleomorphic adenoma is a common tumor of salivary glands [1-2]. It usually affects the large salivary glands, mainly the parotid gland (80% of cases); minor salivary glands are affected in only 8% of cases, principally at the level of the palate. Pleomorphic adenoma at the level of the nasal fossae is extremely rare. In 1929 Denker and Kahler reported for the first time a case of pleomorphic adenoma of the nasal septum. To date, only 107 cases have been reported in the literature. The largest series was reported by Compagno and Wong, which was undertaken between 1949 and 1976. They reported 40 cases of pleomorphic adenomas of nasal fossae, of which 25 developed at the expense of nasal septum [2, 8].

There is a clear predominance in women and Caucasians, most often between 30-60 years of age [4-5]. Clinical signs are poorly specific, common to all nasal tumors and dominated by nasal obstruction of progressive onset in addition to recurrent epistaxis.

Giant pleomorphic adenoma of the nasal cavity

Endoscopic examination usually shows a non-ulcerated polypoid mass of pink or greyish pink colour [1, 7]. Endocranial extension has not yet been documented in the medical literature. Histologically, pleomorphic adenomas of the nasal septum are distinguished from those of the major salivary glands by virtue of their cellularity, which is usually more marked. Epithelial components are predominant and the tumor consists almost entirely of epithelial cells with little or even absent stroma.

Differential diagnosis is the same as for all benign and malignant unilateral tumoral pathologies of the nasal fossae.

The origin of the tumor has not been clearly established. It could proceed from a residual vomeronasal organ or ectopic embryonic epithelial cells of ectodermal origin that have migrated to nasal septum. Pleomorphic adenomas could also develop from epithelial tissues from mature glands.

The only effective treatment is complete surgical removal, most often via an endonasal approach. Paralateronasal and vestibular approaches are reserved for tumors of large volume. Radiotherapy is indicated only in the case of unresectable tumors or because of contraindications to surgery.

Pleomorphic adenoma is a tumor that is characterized by its slow evolution over several years, which requires rigorous and long term follow-up because of the tendency for recurrence and the degeneration of these tumors.

Recurrence, a frequent complication of surgery for pleomorphic adenomas of major salivary glands, rarely occurs in those with an endonasal location [9].

CONCLUSION

Pleomorphic adenomas of the nasal fossae are extremely rare. Their polymorphic histological appearance makes its pathological diagnosis difficult. Treatment

is surgical and most often performed via the endoscopic route. Regular follow-up after removal must be routinely done for several years.

REFERENCES

1. Makeïff M, Youssef B, Guerrier B. Adénome pléomorphe de la cloison nasale. A propos d'un cas. *Ann Otolaryngol Chir Cervicofac.* 1999; 116: 368-371.
2. Compagno J, Wrong RT. Intranasal mixed tumors. *Am J Clin Pathol.* 1977; 68: 213-218.
3. Chomette G, Auriol M. *Histopathologie buccale et cervicofaciale* - Ed Masson Paris, 1996: pp 209-212.
4. Stevenson HN. Mixed tumors of the septum. *Am Otol Rhinol. Laryngol.* 1992; 41: 563-570.
5. Sooy FA. Primary tumors of the nasal septum. *Laryngoscope* 1950; 60: 964-967.
6. Fushiki H , Monjiri M , Maruyama M, Watanabe Y. MRI of intranasal pleomorphic adenoma. *Acta Oto-laryngol.* 2006; 126: 889-891.
7. Sciaretti V, Pasquini E , Frank G , Mondugno GC, Cantaroni C, Franeti G. Endoscopic treatment of benign tumors of the nose and paranasal sinuse—a report 33 cases. *Am J Rhinol.* 2006; 20: 64-71.
8. Kumar SS, Reddy PS , Prabhakar G. Pleomorphic adenoma of the nasal septum—a case report. *Indian J Pathol Microbial.* 2004; 47: 397-398.
9. Chimosi TS, Kontouspoulos AV, Maliotakis P, Bizakis JG. Malignant mixed tumor of the nasal cavity. *Auris Nasus Larynx* 2006; 33: 63-66.