

CASE REPORT

Torticollis with gastroesophageal reflux: Sandifer syndrome

Gontran Ondzotto¹, Jean Rosaire Ibara², Narcisse Ele³, Emmanuel Koutaba⁴

¹ ORL Department - Brazzaville Teaching Hospital, Brazzaville, Congo

² Gastroenterology Department - Brazzaville Teaching Hospital, Brazzaville, Congo

³ Digestive Surgery Department - Brazzaville Teaching Hospital, Brazzaville, Congo

⁴ Pediatric Surgery Department - Brazzaville Teaching Hospital, Brazzaville, Congo

INTRODUCTION

Torticollis is characterized by rotation and lateral flexion of the neck, with or without extension or forward flexion. A thorough evaluation should be performed, as torticollis may indicate a severe disorder. Torticollis related to gastroesophageal reflux (GER) with or without hiatal hernia defines Sandifer syndrome [1]. This disorder of infancy manifests chiefly during meals. Sandifer initially observed the syndrome, which was first described by Kinsbourne in 1964 [2]. We report a new case.

CASE-REPORT

A 16-month-old female was admitted for evaluation of abnormal neck posture of abrupt onset 2 weeks earlier. Her neck was tilted to the right, and her right shoulder was elevated. The abnormal posture was present continuously during the day but resolved during sleep. No swelling was apparent in the sternomastoid muscle. Body temperature was normal.

She had a history of gastroesophageal reflux diagnosed at 24 days of age and managed with metoclopramide 10 mg qid and thickened meals. No previous epi-

(Fr ORL - 2006 ; 91 : 263 - 265)

Key words : Torticollis, Gastroesophageal reflux, Infant.

Submitted for publication: october 2004

Accepted for publication: july 2006

Corresponding author: Gontran Ondzotto

Service ORL - CHU de Brazzaville

BP 13356 - Brazzaville, Congo

e-mail : ondzotto@voila.fr

sodes of abnormal posturing were noted. The parents reported regurgitation and vomiting over the last 6 days. Examination of the neck showed no pain or neuromuscular abnormalities.

Standard radiographs of the neck were normal. Upper gastrointestinal imaging disclosed gastroesophageal reflux and elevation of the cardia. Sandifer syndrome was considered and Nissen fundoplication was performed. The postoperative course was uneventful. The neck posture gradually returned to normal and the reflux symptoms resolved. Physical findings 6 weeks after surgery were normal.

DISCUSSION

The identification of supraglottic manifestations of gastroesophageal reflux has opened up a new area of clinical practice and investigation [3]. These manifestations remain underrecognized, however, for three reasons [4]:

a) reflux symptoms are missing in over half the patients who have supraglottic manifestations, with variations according to the target organ;

b) endoscopy fails to show esophagitis in half the cases, and 24-hour pH monitoring at both the esophagus and pharynx is required for the diagnosis;

c) the supraglottic symptoms may manifest in a single category of organs (lungs, ORL, or oral cavity) or in all the organs affected by the reflux, so that effective detection requires a detailed history covering all the potentially affected areas of the body. In ORL practice, 4 to 10% of patients overall exhibit symptoms and/or lesions related to GER [5]. The prevalence of torticollis among the supraglottic manifestations of GER is difficult to estimate. Sandifer syndrome is underrecognized, studies are scarce, and study populations are not representative [1-2,6].

Sandifer syndrome

Torticollis is a permanent abnormal posture of the head and neck with or without pain and may be chronic or transient. Underlying causes include several severe conditions, indicating that a thorough evaluation should be performed in all patients with torticollis. Congenital tightness of the sternomastoid muscle is the most common cause. Birth defects of the cervical spine, central nervous system lesions, and infections (Grisel's syndrome) can lead to torticollis.

GER is a rare cause of torticollis. The mechanism by which GER may lead to abnormal neck posture is unclear. The posture may be intended to reduce pain caused by reflux esophagitis. Neck muscle spasm in response to acid reflux is another possibility. Onset of Sandifer syndrome usually occurs within the first few weeks or months after birth.

Torticollis may be permanent or paroxysmic in Sandifer syndrome and may be influenced by meals. Importantly, the neurological evaluation and examination of the sternomastoid and trapezius muscles show normal findings [6]. Reflux symptoms (vomiting, regurgitation, pain, and irritability after feedings) consistently antedate the development of torticollis, and most patients are on pharmacotherapy at the time of onset of the torticollis. Endoscopy is of limited diagnostic value, as esophagitis is often absent. Therefore, 24-hour pH monitoring is the reference standard for the diagnosis. Very low pH values (4 to 5) are often found over the 24-hour monitoring period. Esophageal manometry can be used but requires two recordings, one distal and one proximal, resulting in a cumbersome procedure. Although technically complex, a 24-hour pH probe equipped with an infused cuff and integrated electrodes is valuable for distinguishing among types of relaxation of the lower esophageal sphincter. Uppergastrointestinal imaging, which was performed in our patient, is not required to confirm the diagnosis of GER but serves to evaluate reflux severity and to look for hiatal hernia.

When Sandifer syndrome is suspected, no treatments specific of the abnormal neck posture should be used. Effective management of the GER is mandatory. Small frequent feedings help to reduce the volume that is available for reflux and to increase the periods of gastric neutralization, although the number of postprandial reflux events is increased also [7]. Cereal, tapioca or pectin can be used to thicken the formula. Prokinetic agents tid or qid increase lower esophageal sphincter tone and accelerate gastric emptying; some of them improve gastrointestinal motility. Antacids include sodium alginate, coating agents, and acid secretion inhibitors. Proton pump inhibitors have produced good

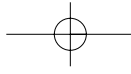
results [8]. The mean recommended dosage is 1.5 mg/kg once a day. Second-generation proton pump inhibitors ensure optimal acid-secretion inhibition for 18 to 20 hours and are highly effective in relieving GER symptoms [3]. Failure of appropriate pharmacotherapy and dietary modifications should lead to an evaluation of the need for antireflux surgery [7] using Nissen fundoplication [1,6,9]. Neck posture returns to normal gradually after resolution of the reflux.

CONCLUSION

In addition to the main causes of torticollis in pediatric patients (congenital torticollis, birth defects, neurological disorders, infections, and others), gastrointestinal symptoms such as reflux should be sought carefully in order to determine whether Sandifer syndrome is a possible diagnosis. The management consists in alleviating the reflux via dietary measures, prokinetic agents, and H₂ antagonists or proton pump inhibitors. When the treatment effect is inadequate, surgery should be considered.

REFERENCES

1. Nana Yakkara CS, Ramompaton JY. Sandifer syndrome: an over looked diagnosis? *Dev Med Child Neurol.* 1985; 27: 816-819.
2. Kinsbourne M. Hiatus hernia with contorsions of the neck. *Lancet* 1964; 1: 1058-1061.
3. Mainguet P. Les manifestations supraglottiques du RGO. *Acta Endoscopica* 2004 ; 34 : 311-319 .
4. Mainguet P. Les manifestations supraglottiques du RGO. ALN Editions, Nancy 2003, p.46.
5. Toohill RJ, Mushtag E, Lehman RH. Otolaryngologic manifestations of gastroesophageal reflux. In "Sacritan T, Alvarez-Vincent JJ, Bartual J et al. Eds Proceedings of XIV World Congress of otolaryngology-Head and Neck Surgery. Amsterdam, Kugler et Ghedini Publications 1990, p 3005-3009.
6. Tekou H, Felou A, Akue B, Senah KC, Dagnrah PC, Atanley R. Le syndrome de Sandifer. *Tunisie Med.* 1998; 76: 88-90.



Sandifer syndrome

7. Le Luyer B, Le Roux P, Briquet MT, Bouloche J. Traitement médical du RGO. Rev Int Pédiatr. 1999; 30 : 94-98.
8. Gunasekaran T, Hassal EG. Efficacy and safety of omeprazole for severe gastroesophageal reflux in children. Gastroesophageal 1993; 123: 148-158.
9. Duffy JP, Maggard M, Hiyama DT, Atkinson JB, McFadden DN, Hines OJ. Laparoscopic Nissen fundoplication improves quality of life in patients with atypical symptoms of gastroesophageal reflux. Am Surg. 2003; 69: 833-838.

